DOI: 10.7860/JCDR/2026/88406.24750

Case Report

Radiology Section

# Obstructed Hemi-vagina with Ipsilateral Renal Agenesis Syndrome: A Case Report

YASHODHAN S DHONUKSHE[1], DIVYASHREE KOPPAL[2], SATISH D PATIL[3]

BY-NC-ND

## ABSTRACT

The Obstructed Hemi-vagina with Ipsilateral Renal Agenesis (OHVIRA) syndrome, or Herlyn-Werner-Wunderlich (HWW) syndrome, is a rare congenital disorder characterised by abnormalities of the Müllerian ducts and ipsilateral renal agenesis. Hereby, the authors present a case of a 15-year-old female who presented with lower abdominal pain and irregular menstrual cycles for one year. On complete evaluation of the pelvis using ultrasound, Computed Tomography (CT) and Magnetic Resonance Imaging (MRI), findings of right renal agenesis with compensatory left renal hypertrophy, Bicorporeal septate uterus with bicollis (uterine duplication anomaly), Complete obstruction of the right hemi-vagina by a transverse vaginal septum, and haematocolpos due to retained menstrual blood were seen, which are diagnostic of OHVIRA syndrome with right hemi-vaginal obstruction and ipsilateral renal agenesis, for which the patient underwent diagnostic hysterolaparoscopy with vaginal septal resection. The collection was drained from the right hemi-vagina and contained thick, blood-stained, purulent material, with *E. coli* growth on culture. The case shows the significance of early diagnosis of the syndrome in an adolescent female patient. If corrected at the right time using surgical techniques, other complications are avoided, such as secondary infections, chronic pelvic inflammatory disease, endometriosis, and infertility.

**Keywords:** Haematocolpos, Haematometra, Herlyn-Werner-Wunderlich syndrome, Müllerian duct anomaly, Purulent material

## CASE REPORT

A 15-year-old female was referred to Department of Radiology for further assessment of a suspected ectopic right kidney identified on an ultrasonography examination performed elsewhere. She had attained menarche and previously experienced regular menstrual cycles every 20 days, lasting 4-5 days, without dysmenorrhoea. During the preceding year, she developed intermittent lower abdominal pain accompanied by irregular menstrual cycles. There was no history of fever, sexual activity, and the family history was non contributory.

Abdominal examination was unremarkable. Her haemoglobin level was 9.5 g/dL. Renal function parameters were within normal limits, including serum urea 25 mg/dL, serum creatinine 0.6 mg/dL, and serum uric acid 4.4 mg/dL.

The patient was initially evaluated at an outside centre with transabdominal ultrasonography, where an ectopic right kidney was suspected. She was referred to study Institution for a Non-contrast Computed Tomography (NCCT) of the abdomen to assess for the absence of the right kidney. Right renal agenesis was established with no evidence of ectopic/atrophic kidney. The left kidney showed compensatory hypertrophy with normal shape and attenuation. Bicorporeal uterus was observed with significant distension of the vagina [Table/Fig-1].

The ultrasound examination of the abdomen revealed an empty right renal fossa with compensatory hypertrophy of the left kidney measuring approximately 13×5.4×6.5 cm (CC×AP×TR) [Table/Fig-2]. Nevertheless, echogenicity and corticomedullary differentiation of the left kidney were normal.

The longitudinal and coronal ultrasound images of the pelvis showed two separate uterine horns with two separate endometrial cavities and cervical canals [Table/Fig-3]. The uterine horns were widely divergent (>110 degrees) and had a fundal cleft (depth >1 cm and >50% of the myometrial thickness).

A significantly distended right hemi-vagina was seen with a hypoechoic collection having low-level internal echoes, characteristic of haematocolpos (volume of the collection was approximately 82

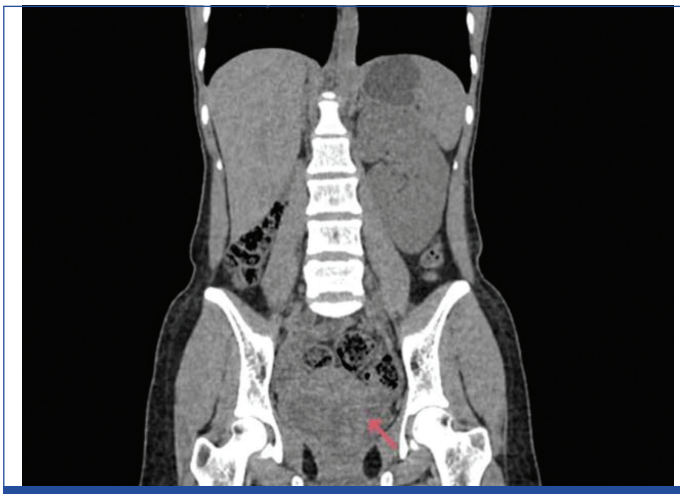

**[Table/Fig-1]:** Coronal non contrast CT abdomen-pelvis demonstrates absent right kidney, compensatory hypertrophy of left kidney. Abnormal uterine contour with collection in the vaginal canal (pink arrow).

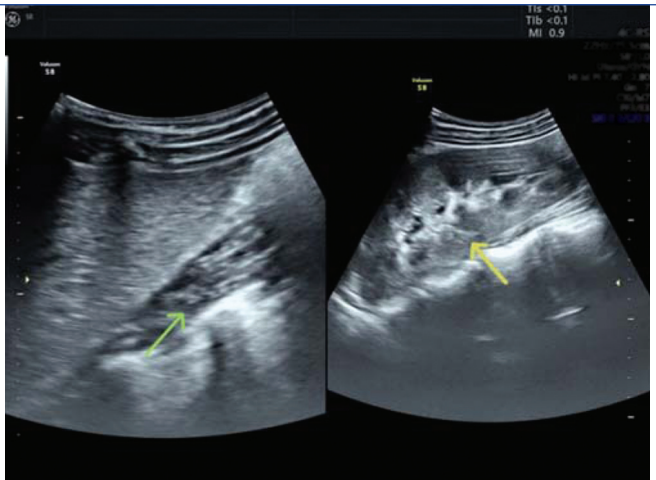

**[Table/Fig-2]:** Transabdominal ultrasound longitudinal view showing empty right renal fossa (green arrow). The left kidney showed compensatory hypertrophy with normal echogenicity and corticomedullary differentiation (yellow arrow).

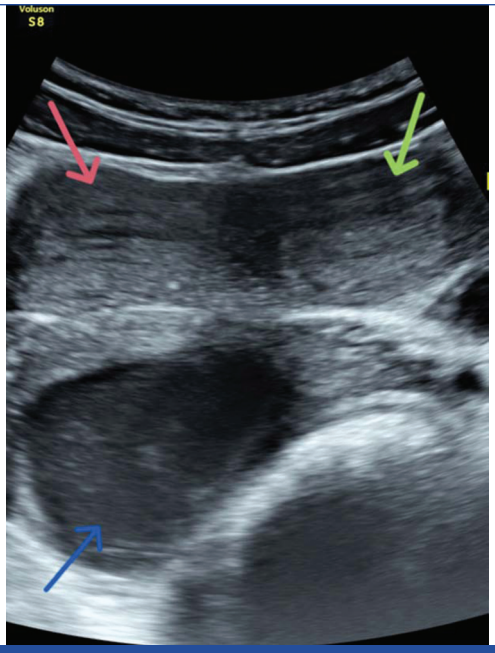


**[Table/Fig-3]:** Transabdominal ultrasound axial view of the pelvis demonstrating both uterine horns (pink arrow-right horn) (green arrow-left horn) with visible endometrium and two distinct cervical canals in comparable planes. Moderate amount of hypoechoic collection is seen in the right hemi-vagina (blue arrow). The left hemi-collis and left vaginal canal are patent and collapsed.

cc) [Table/Fig-4]. The right endometrial canal showed no collection. The left cervical canal and left hemi-vagina appeared collapsed. The left uterine horn was normal in size with no evidence of any collection in the endometrial canal. Incidentally, a dominant follicle was noted in the right ovary. These results were highly suggestive of OHVIRA syndrome. The presence of a bicorporeal septate uterus with bicollis, obstructed hemi-vagina, and ipsilateral renal agenesis was pathognomonic in making the diagnosis.

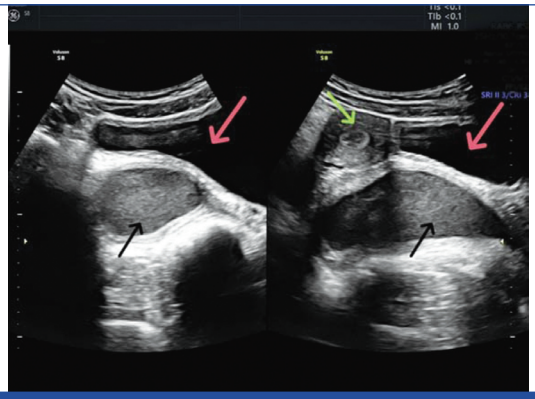

**[Table/Fig-4]:** Transabdominal sagittal image demonstrating the anatomic relationships between the markedly dilated right hemi-vagina (black arrow) and adjacent pelvic structures. The relationship to the bladder (pink arrow) and pelvic side wall musculature with uterus (green arrow) is clearly delineated.

Further MRI of the pelvis was performed. T1- and T2-weighted sequences, which revealed a bicorporeal septate uterus with bicollis and two vaginal canals [Table/Fig-5]. A 7-8 mm thick transverse septum causing complete obstruction of the upper two-thirds of the right hemi-vagina was demonstrated [Table/Fig-6]. The right hemi-vagina was distended with T1-intermediate signal and T2-hyperintense contents exhibiting T2 shading and mild diffusion restriction on Diffusion-weighted Imaging (DWI) sequence, whereas the left hemi-vagina was collapsed and patent.

These MRI findings were consistent with the ultrasound examination, suggesting a bicorporeal septate uterus with bicollis, two vaginal canals with obstruction of the right hemi-vagina, and right renal agenesis, and were classified as U (Uterine)3c Cervical (C)2 Vaginal (V)2/3 according to the European Society of Human Reproduction and Embryology (ESHRE)/European Society for Gynaecological Endoscopy (ESGE) classification system [1].

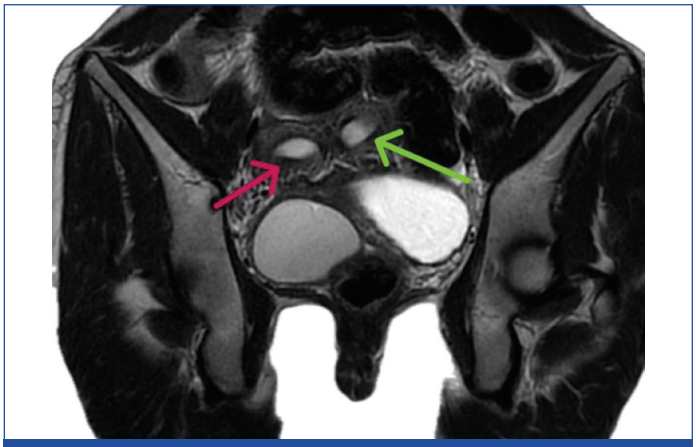

**[Table/Fig-5]:** Coronal T2-weighted MRI at the level of the uterus showing bicorporeal uterus with two distinct uterine horns (green arrow- left horn, red arrow-right horn).

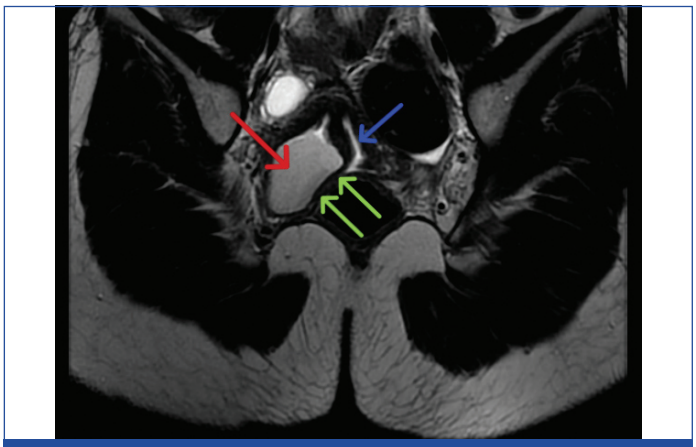

**[Table/Fig-6]:** Coronal T2-weighted MRI of the pelvis demonstrating right hemi-vaginal obstruction with T2-hyperintense collection in the right hemi-vagina (red arrow). The transverse vaginal septum is seen extending down from the medial wall of the right hemi-collis and is laterally attached to the right lateral wall of the right hemi-vagina (green arrow). Patent left hemi-vagina is clearly delineated (blue arrow).

The patient underwent combined diagnostic laparoscopy with hysteroscopic septal resection under spinal anaesthesia, to confirm the Müllerian anomaly and evaluate the pelvic anatomy. Intraoperatively, laparoscopy revealed the external morphology of the uterus with two separate uterine horns [Table/Fig-7]. The obstructing right hemi-vaginal septum was resected, and approximately 82-85 mL of blood-stained, purulent, pus-like material was drained, suggesting pyocolpos. Culture of the purulent fluid yielded *Escherichia coli*. The procedure was completed without any complications, and a vaginal pack was left in place for 24 hours for haemostasis.

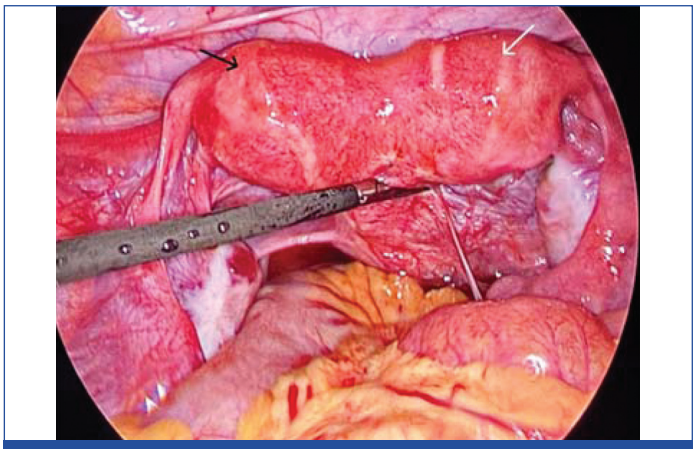

**[Table/Fig-7]:** Laparoscopic image showing bicorporeal uterus with two distinct uterine horns; right horn (black arrow) and left horn (white arrow).

The postoperative recovery was uneventful. A follow-up ultrasound was performed on postoperative day 5, which demonstrated complete resolution of the collection [Table/Fig-8], and the patient remained asymptomatic at the 1-month and 6-month follow-up visits.

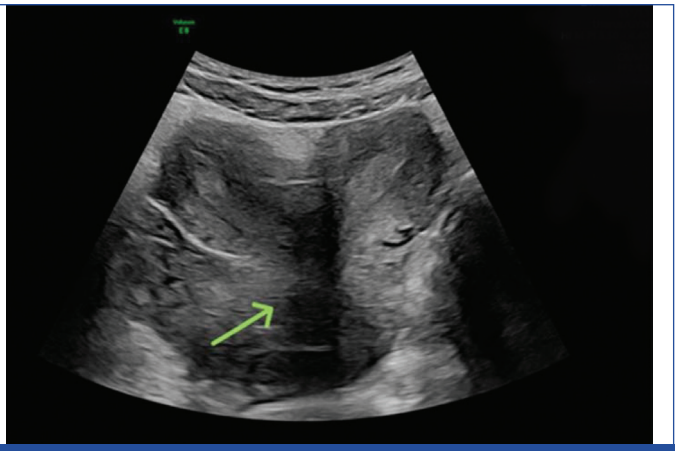

**[Table/Fig-8]:** Postoperative ultrasound image following hysterolaparoscopy and vaginal septum resection demonstrating no evidence of any collection in the right hemi-vagina (green arrow).

## DISCUSSION

The OHVIRA syndrome, formerly called HWW syndrome is an exceptional female congenital anomaly of the reproductive and urinary system [2,3]. The typical presentation includes a pathologic triad: (a) uterus didelphys (complete duplication of the uterus); (b) unilateral blind hemi-vagina with transverse vaginal septum; (c) ipsilateral renal agenesis, though anatomical variants have been reported [2,4].

This syndrome is caused by inappropriate development of the Müllerian (paramesonephric) and Wolffian (mesonephric) ducts during embryogenesis. The Wolffian ducts, which contribute to the development of the kidneys and upper urinary tract, also play an inductive role in Müllerian duct fusion. The coexistence of reproductive tract and urinary tract malformations is thought to result from defects in the vertical and/or lateral fusion of the mesonephric and paramesonephric ducts [2]. It is most commonly diagnosed during adolescence after menarche, when patients present with cyclical pelvic pain, dysmenorrhoea, menstrual irregularities, primary amenorrhea, or recurrent urinary tract infections [2,3].

Serious complications such as chronic infections, infertility and malignancy arising from the obstructed cervix or vagina have been reported in untreated cases, highlighting the importance of prompt diagnosis and appropriate management [5].

Pyocolpos is an unusual complication of OHVIRA syndrome. In present patient, culture of the drained purulent material grew Escherichia coli, suggesting an ascending infection secondary to retained secretions. Recent reports have described delayed diagnosis into adulthood and have emphasised the value of systematic imaging evaluation in females with unilateral renal agenesis [5,6]. In contrast, present patient was diagnosed at an earlier stage, allowing timely surgical intervention and preservation of future reproductive potential.

Case reports in recent years also demonstrate the anatomical diversity of OHVIRA syndrome and report uncommon cases in which there was cervical atresia, obstructed hemi-vagina, and a non-communicating uterine horn. MRI played a major role in outlining the complex Müllerian anatomy and was used to plan individual surgical management in both reports including hemihysterectomy and the removal of the non-communicating uterine horn where it was not possible to perform a resection of the septum [7,8].

The differential diagnoses of OHVIRA are unicornuate uterus with rudimentary horn, vaginal atresia, imperforate hymen, transverse vaginal septum, and Gartner duct cyst. These anomalies can be distinguished by MRI, and the treatment is directed accordingly. Management of OHVIRA syndrome requires multidisciplinary collaboration among the gynaecologists, radiologists, and nephrologists. Long-term follow-up is especially important in patients with a solitary kidney to monitor renal function, regular menstrual cycles with appropriate menstrual flow and fertility status.

## CONCLUSION(S)

The OHVIRA syndrome is an infrequent but clinically significant condition that should be considered in adolescent females presenting with menstrual irregularities and pelvic pain. The present case shows the importance of evaluating both reproductive and urinary systems. A key contribution of this report is a rare anatomical variant of bicorporeal septate uterus with bicollis, obstructed right hemi-vagina due to a transverse vaginal septum, characterised using ultrasound and MRI and confirmed intraoperatively with complex infective collection (pyocolpos). The case highlights the role of MRI in defining complex Müllerian anomalies, appropriate surgical planning, and enabling timely intervention to prevent complications.

## REFERENCES


[1] Grimbizis GF, Gordts S, Di SpiezioSardo A, Brucker S, De Angelis C, Gergolet M, et al. The ESHRE/ESGE consensus on the classification of female genital tract congenital anomalies. Hum Reprod. 2013;28(8):2032-2044. Doi: 10.1093/humrep/det098.

[2] Negrão E, Flor-de-Lima B, Dias SC, Guimarães L, Madureira AJ. Herlyn-Werner-Wunderlich syndrome: A case report in a young woman, with literature review. Radiol Case Rep. 2022;17(6):1991-1995. Doi: 10.1016/j.radcr.2022.03.064.

[3] Zhang H, Ning G, Fu C, Bao L, Guo Y. Herlyn-Werner-Wunderlich syndrome: Diverse presentations and diagnosis on MRI. Clin Radiol. 2020;75(6):480.e17–480.e25. Doi: 10.1016/j.crad.2020.01.016.

[4] Ahmad Z, Goyal A, Das CJ, Deka D, Sharma R. Herlyn-Werner-Wunderlich syndrome presenting with infertility: Role of MRI in diagnosis. Indian J Radiol Imaging. 2013;23(3):243-246. Doi: 10.4103/0971-3026.120283.

[5] Grammatis AL, Ajibade F, Warakaulle D, Dada T. Obstructed hemi-vagina with ipsilateral renal agenesis syndrome in adulthood: A diagnostic challenge. Diagnostics (Basel). 2023;13(21):3377. Doi: 10.3390/diagnostics13213377.

[6] Malanowska-Jarema E, Starczewski A, Osnytska Y, Krzyścin M, Sowińska-Przepiera E, Balzarro M, et al. Obstructed Hemivagina with ipsilateral renal agenesis: A challenging case report and a management flow chart. J Clin Med. 2023;12(23):7227. Doi: 10.3390/jcm12237227.

[7] Tan YR, Nadarajah R, Tan HK. Obstructed Hemivagina and Ipsilateral Renal Anomaly (OHVIRA) Syndrome: A case report. Cureus. 2026;18(1):e101002. Doi: 10.7759/cureus.101002.

[8] Bakhsh H, Hamdoun A. Obstructed hemivagina with ipsilateral renal anomaly: Radiological diagnosis, outcome of surgical management and literature review. Diagnostics. 2026;16(4):537. Available from: https://doi.org/10.3390/diagnostics16040537.



**PARTICULARS OF CONTRIBUTORS:**

1. Junior Resident, Department of Radiology, Shri B.M. Patil Medical College and BLDE Deemed to be University (BLDE DU), Vijayapura, Karnataka, India.
2. Senior Resident, Department of Radiology, Shri B.M. Patil Medical College and BLDE Deemed to be University (BLDE DU), Vijayapura, Karnataka, India.
3. Professor and Head, Department of Radiology, Shri B.M. Patil Medical College and BLDE Deemed to be University (BLDE DU), Vijayapura, Karnataka, India.

**NAME, ADDRESS, E-MAIL ID OF THE CORRESPONDING AUTHOR:**
Dr. Divyashree Koppal,
Senior Resident, Department of Radiology, Shri B.M. Patil Medical College and BLDE Deemed to be University (BLDE DU), Vijayapura-586103, Karnataka, India.
E-mail: divyashreerkpcc@gmail.com



**PLAGIARISM CHECKING METHODS:** [Jain H et al.]

- Plagiarism X-checker: Mar 10, 2026
- Manual Googling: Jul 22, 2026
- iThenticate Software: Jul 25, 2026 (2%)

**ETYMOLOGY:** Author Origin

**EMENDATIONS:** 6

**AUTHOR DECLARATION:**

- Financial or Other Competing Interests: None
- Was informed consent obtained from the subjects involved in the study? Yes
- For any images presented appropriate consent has been obtained from the subjects. Yes

Date of Submission: **Feb 21, 2026**
Date of Peer Review: **May 27, 2026**
Date of Acceptance: **Jul 28, 2026**
Date of Publishing: **Dec 01, 2026**